
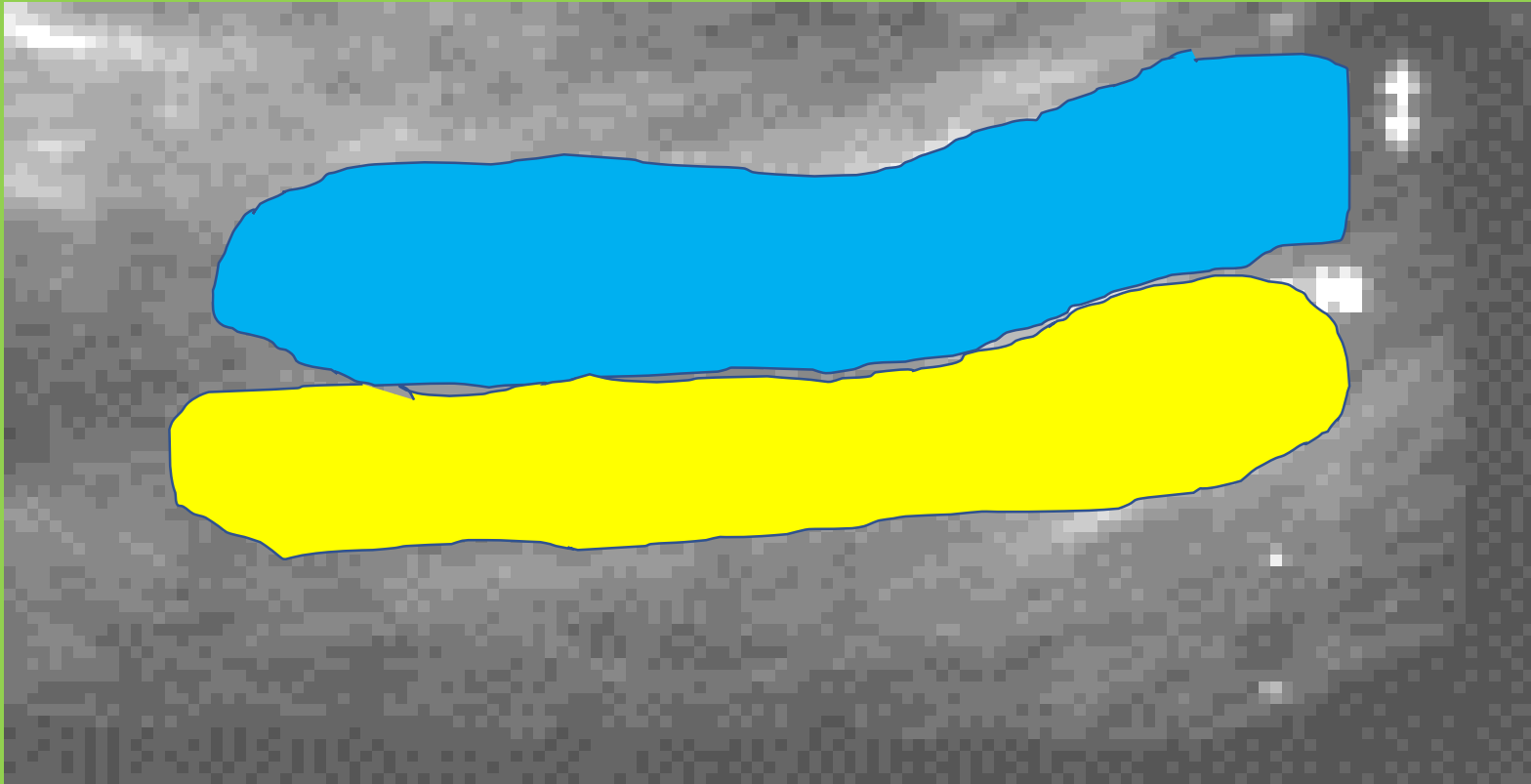



Missed Aortic Aneurysm



Examination demonstrates a longitudinal dissecting aneurysm which was missed involving the abdominal aorta

2 lumens **blue** and **yellow** are present – should be only 1 lumen -red

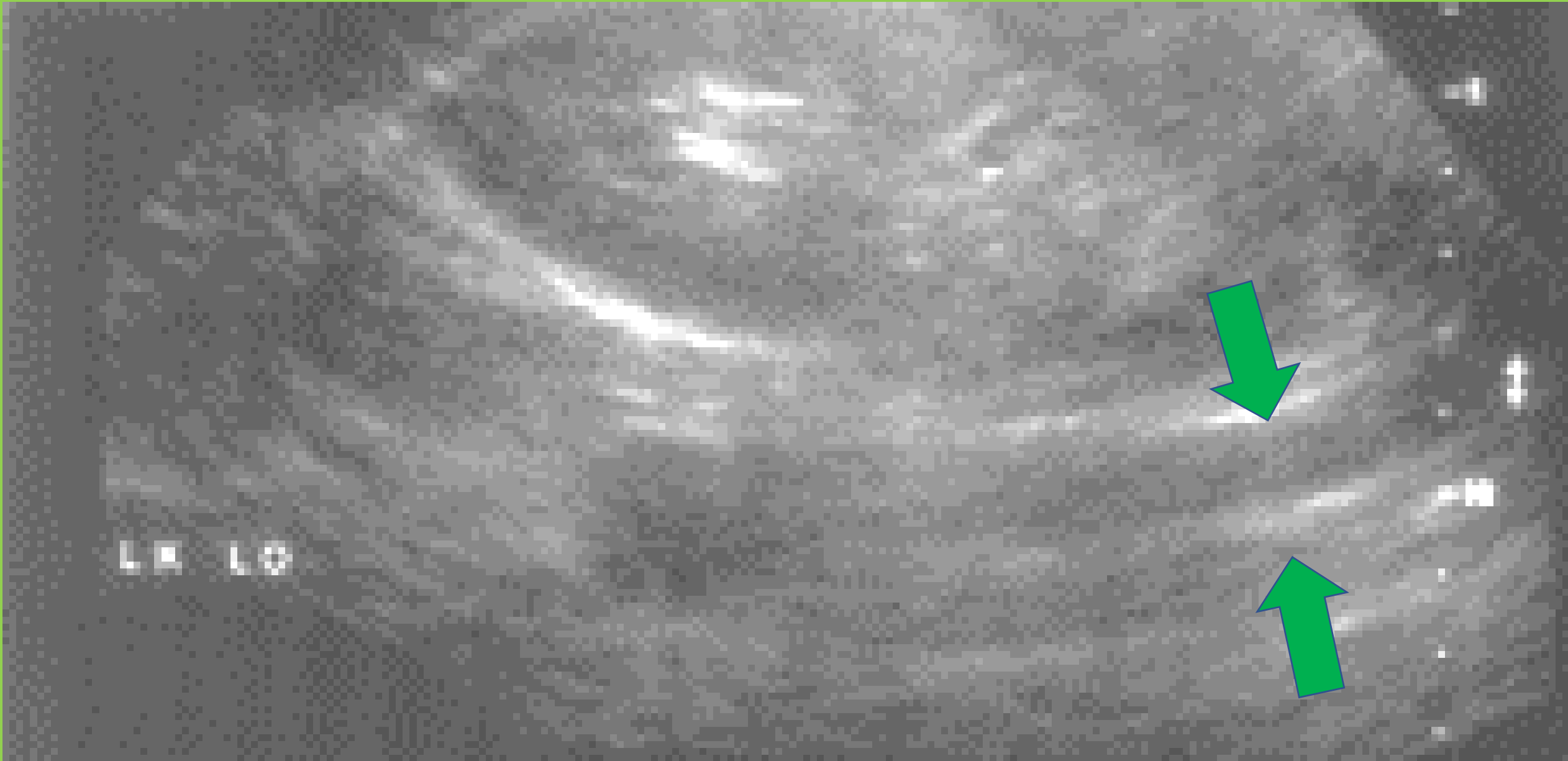


2 lumens along the long axis





2 lumens along the long axis



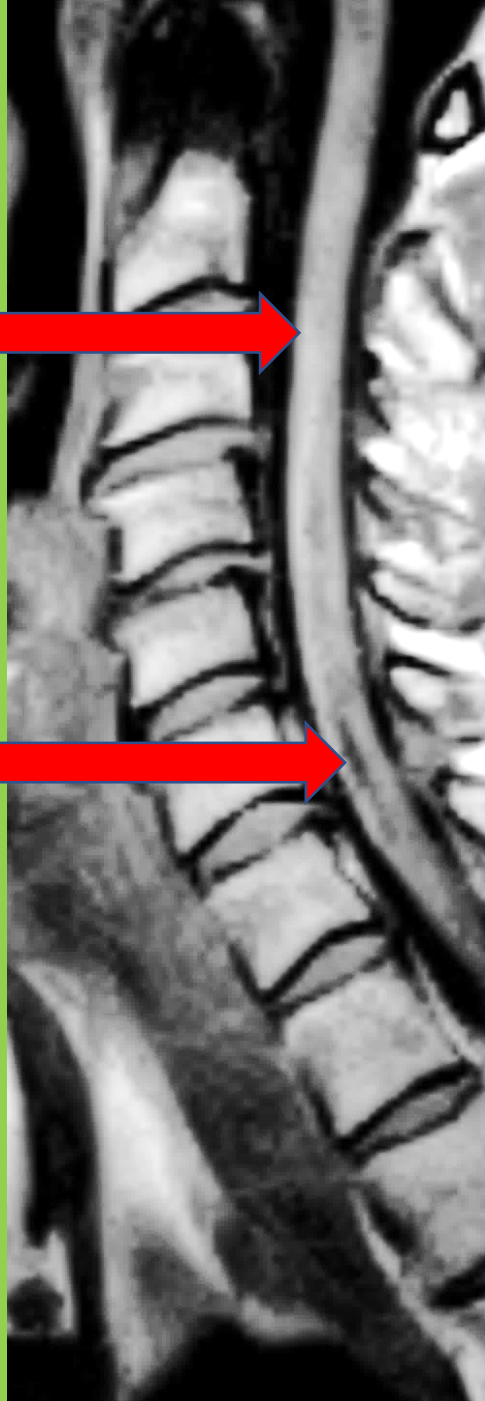
Irreversible cord
injury

3 weeks –post operative weakness

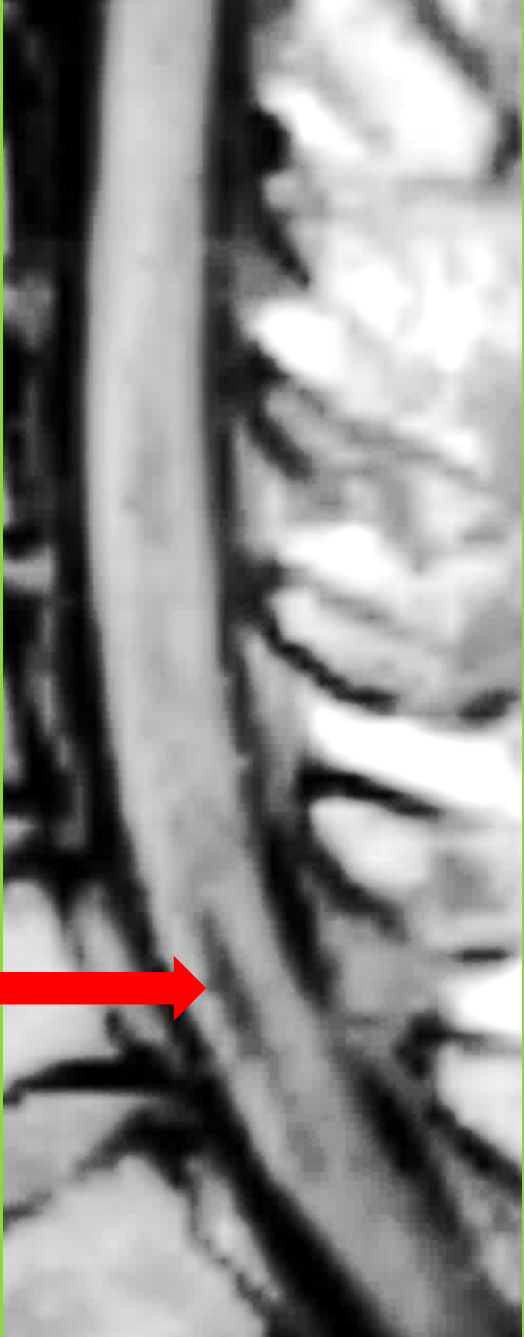Normal cervical cord



Black is dead cord



Black region is destroyed cord



Black region now filled with
red is destroyed cord

